

# Diagnosis and Management in Fibrodysplasia Ossificans Progressiva (FOP)

Christiaan Scott, MD and Raphaella Stander, MBCHB

# Continuing Education Information



JOINTLY ACCREDITED PROVIDER™  
INTERPROFESSIONAL CONTINUING EDUCATION

In support of improving patient care, this activity has been planned and implemented by American Academy of CME, Inc. and CheckRare CE. American Academy of CME, Inc. is Jointly accredited by the Accreditation Council for Continuing Medical Education (ACCME), the Accreditation Council for Pharmacy Education (ACPE), and the American Nurses Credentialing Center (ANCC), to provide continuing education for the healthcare team.

American Academy of CME, Inc., designates this enduring material for a maximum of 1.0 *AMA PRA Category 1 Credits*™. Physicians should claim only the credit commensurate with the extent of their participation in the activity.

**Learning Objective:** Apply best practices for suspecting and diagnosing FOP; List best practices for managing young children with FOP; Identify best practices to manage older children and adults with FOP.

**Planner/Faculty Educator** Christiaan Scott, MD, discloses the following relevant financial relationships with ineligible companies: Grant/Research Support: Regeneron\*, Incyte\*, Janssen\*, Roche\*; Speaker's Bureau: Ipsen\*, Regeneron\*, Springer\*, Janssen\*

\*Relationships have ended

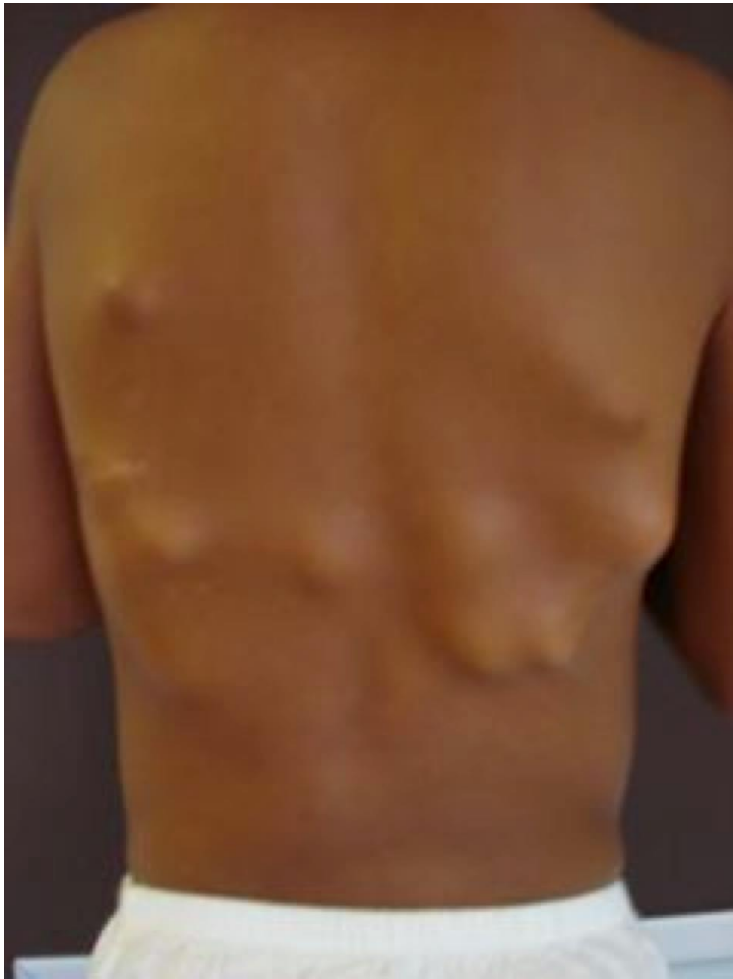**Planner/Faculty Educator** Raphaella Stander, MBCHB, has no relevant financial relationships with any ineligible companies.

All other planners and reviewers for this activity have no relevant financial relationships with any ineligible companies.

All relevant financial relationships listed have been mitigated. This activity will discuss off-label uses and investigational agents.

This accredited continuing education program is supported by an educational grant from Ipsen Biopharmaceuticals .

CASE 1: Pt A - Diagnosing FOP

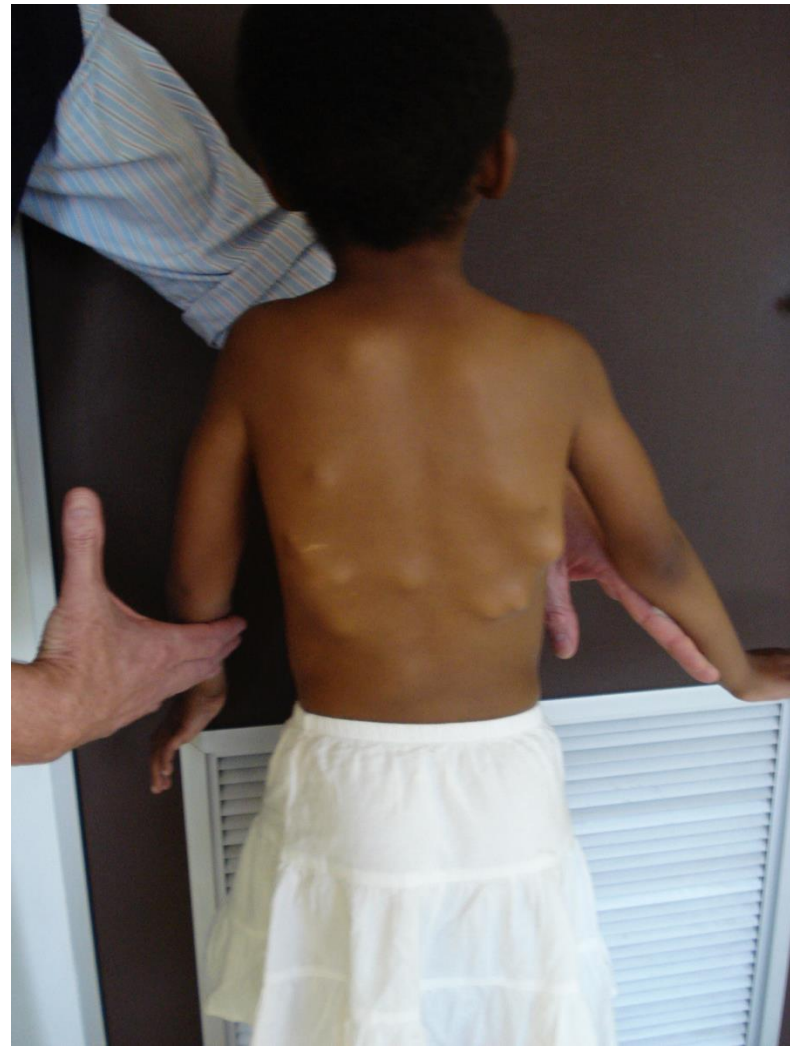

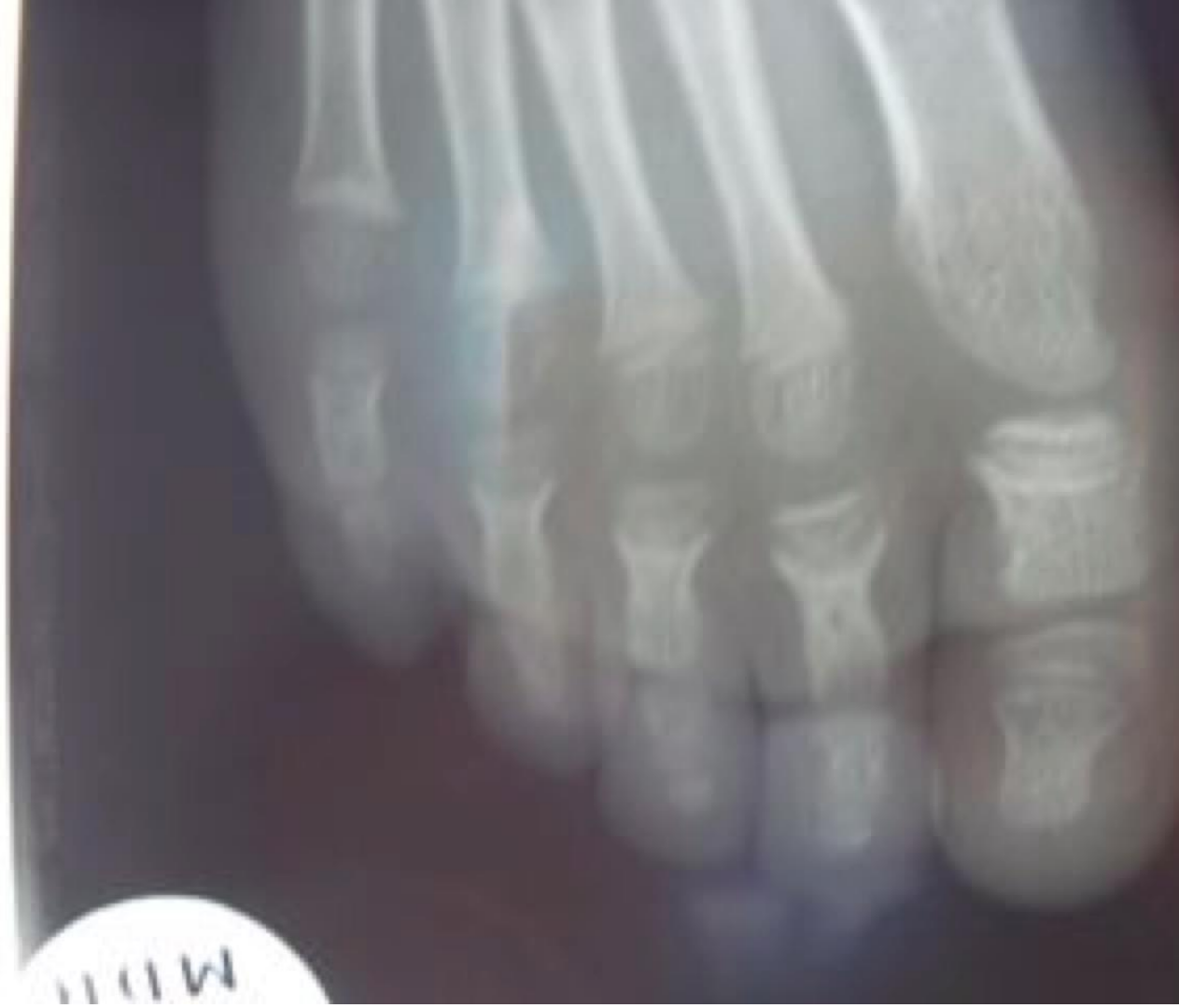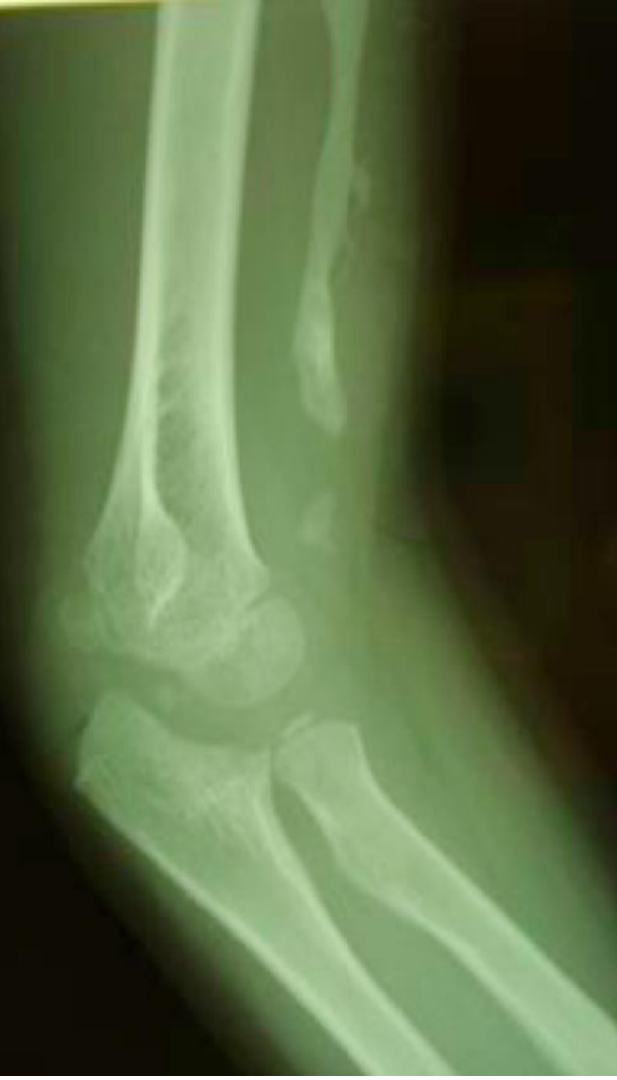4 yo girl.

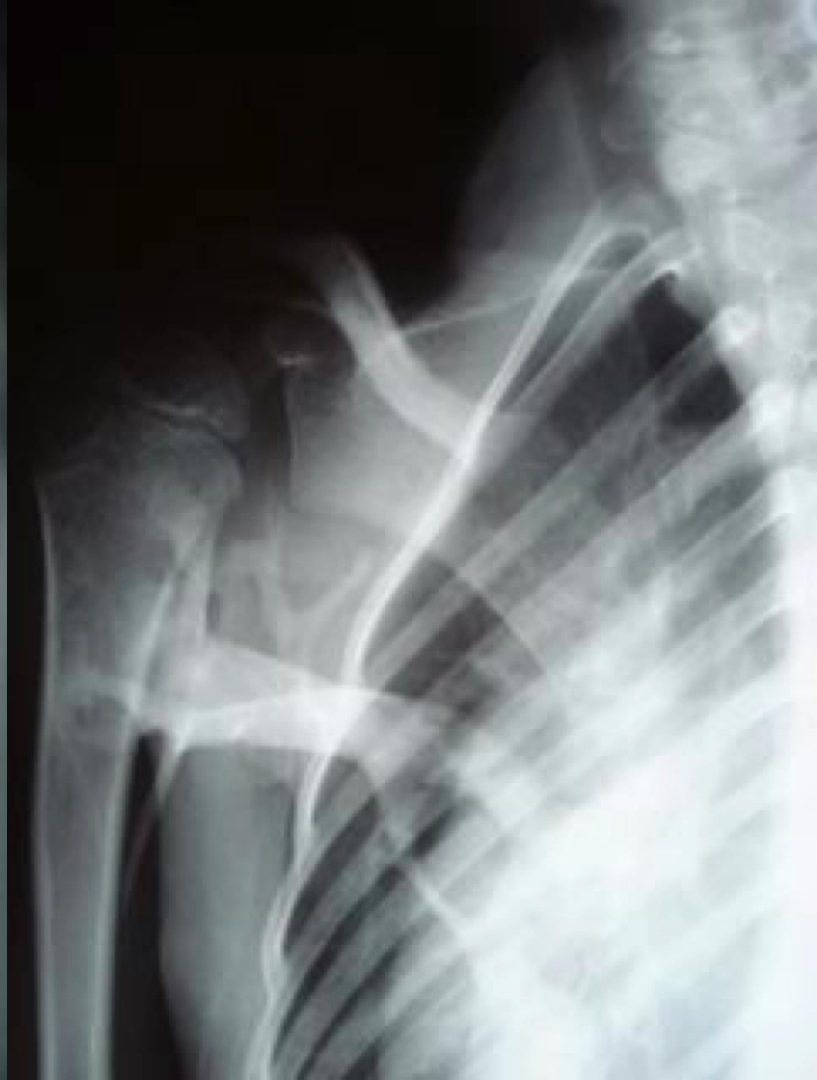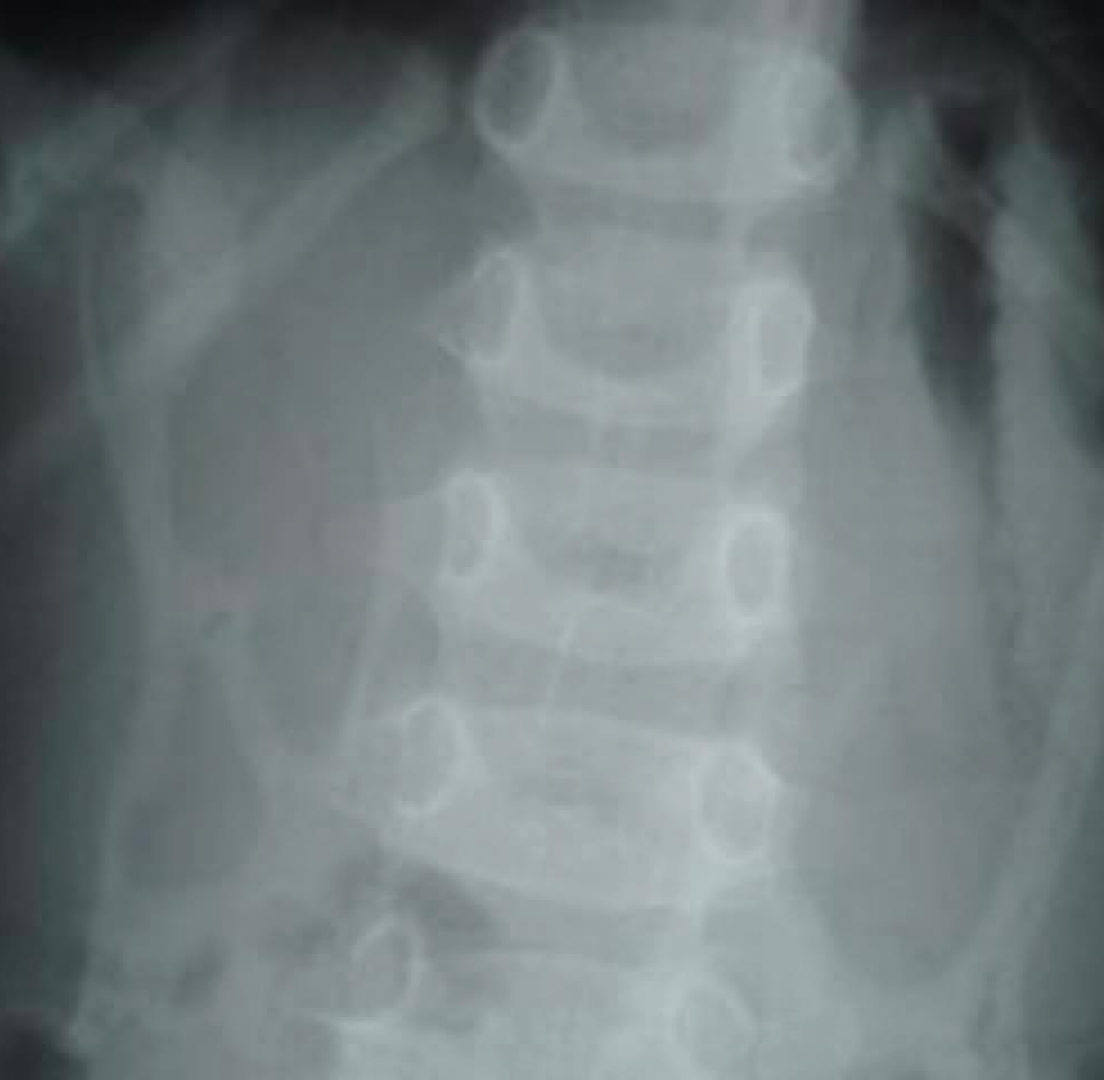2 months of  
painful lump  
over left  
scapula

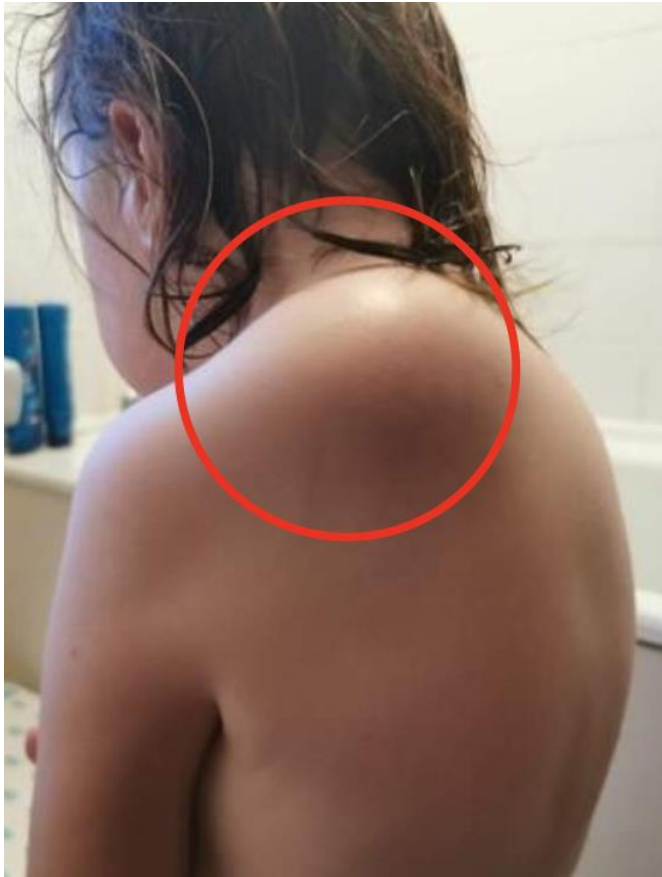CRP 24,  
FBC, CK,  
LDH all  
normal

*Biopsy?*

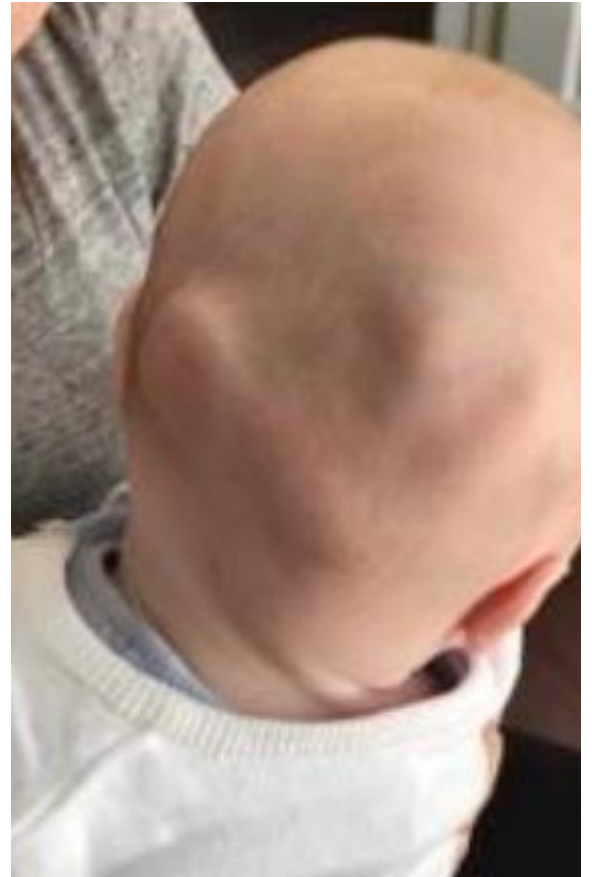








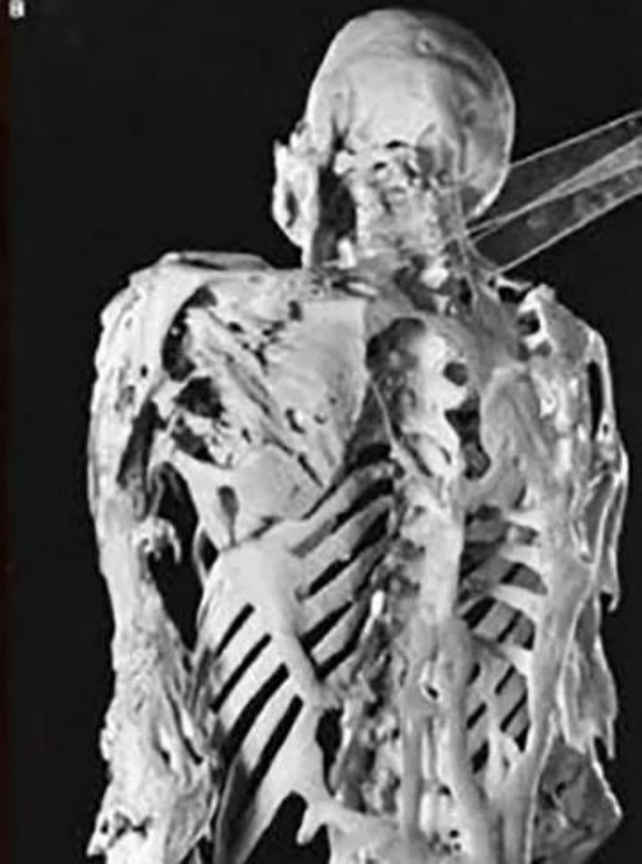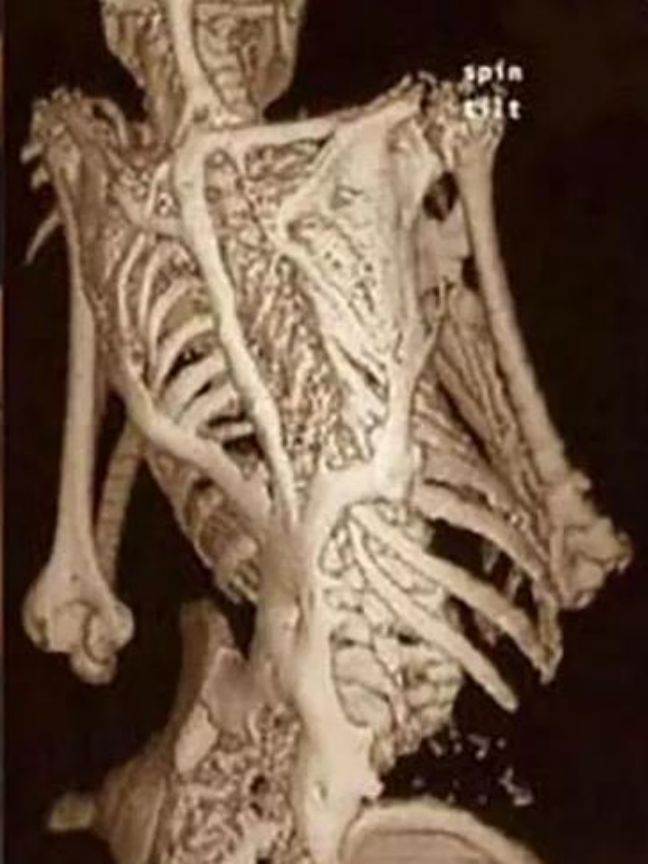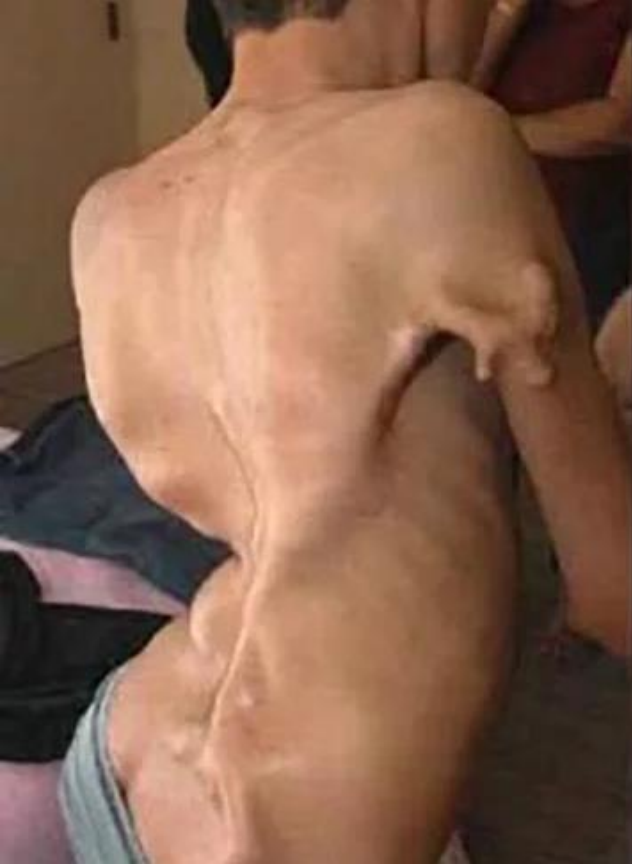Why is a Biopsy  
Contra-indicated?



**First**




**Do No Harm**

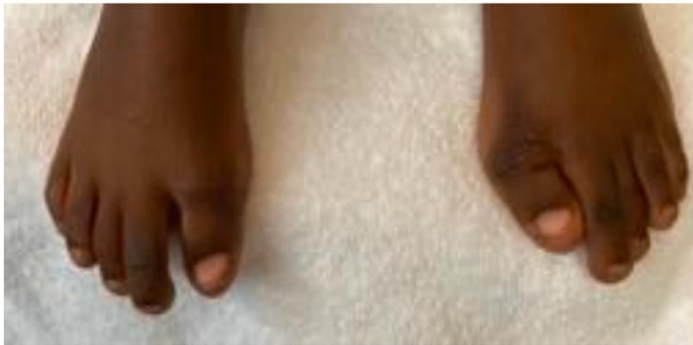
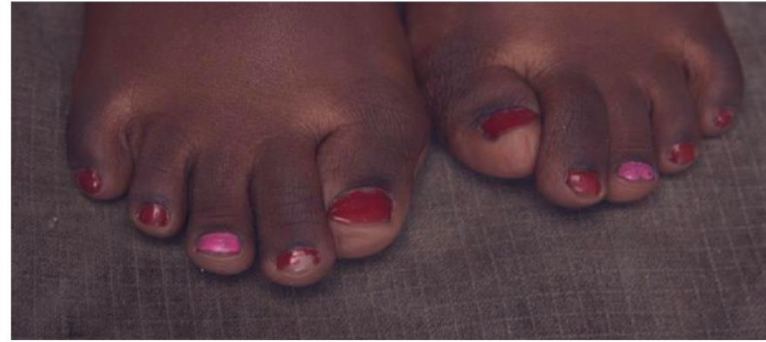
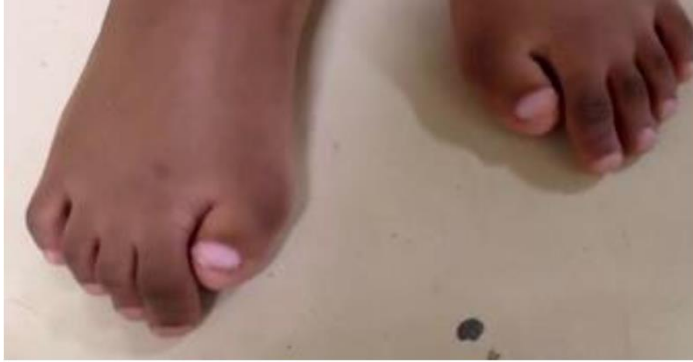Fibrodysplasia Ossificans Progressiva

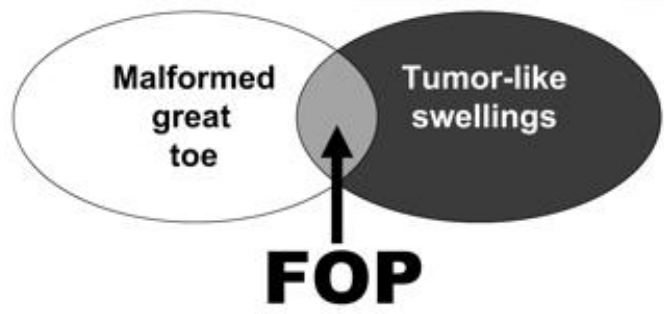
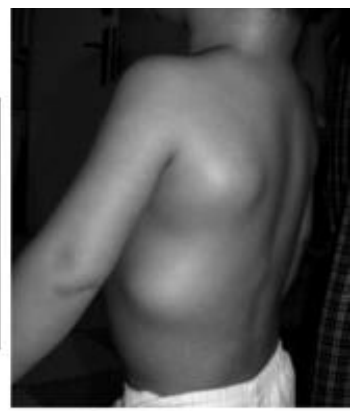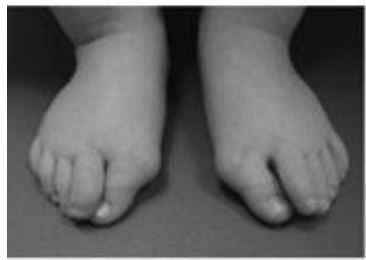Diagnosis is Easy



Misdiagnosis is harmful



**Examples of big toes that are short, big toes missing the middle joints and big toes pushed inward from malformation.**



Differential diagnosis:

- Isolated congenital malformations
- Brachydactyly (isolated)
- Juvenile bunions
- Sarcoma
- Desmoid tumor
- Aggressive juvenile fibromatosis
- Lymphedema

Lieutaud cites a case, reported by Blanchard,<sup>213</sup> in which, in a case of hydatid disease, the stomach contained 90 pounds of fluid.

**Ankylosis of the articulations**, a rare and curious anomaly, has been seen in the human fetus by Richaud, Joulin, Bird, and Becourt. Ankylosis of all the joints, with muscular atrophy, gives rise to a condition that has been popularly termed "ossified man." A case of this nature is described,<sup>a</sup> the patient being a raftsman, aged seventeen, who suffered with inflammatory symptoms of the right great toe, which were followed in the next ten years by progressive involvement of all the joints of the extremities, and of the vertebrae and temporo-maxillary articulations, with accompanying signs of acute articular rheumatism. At the age of thirty-one the pains had subsided, leaving him completely disabled. All the joints except the fingers and toes had become ankylosed, and from nonusage the muscles had atrophied (Fig. 268). There were no dislocations, anesthesia, or bedsores, and the viscera were normal; there were apparently no gouty deposits, as an examination of the urine was negative.

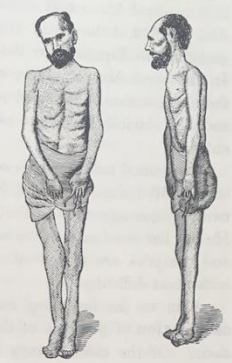


Fig. 268.—Ossified man (front and side views).

J. R. Bass, the well-known "ossified man" of the dime museums, has been examined by many physicians, and was quite intelligent and cheerful in spite of his complete ankylosis. Figure 269 represents his appearance in 1887.

Percy<sup>b</sup> speaks of a man named Simoore, born in 1752, who at the age of

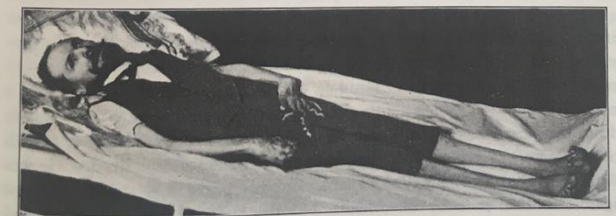

Fig. 269.—J. R. Bass, the "ossified man."

fifteen was afflicted with ankylosis of all the joints, and at different angles. He was unable to move even his jaw, and his teeth had to be extracted in order to supply him with nourishment. Even his ribs were ankylosed; his chest

<sup>a</sup> International Jour. of Surg., Feb., 1889.

<sup>b</sup> 302, iv., 245.

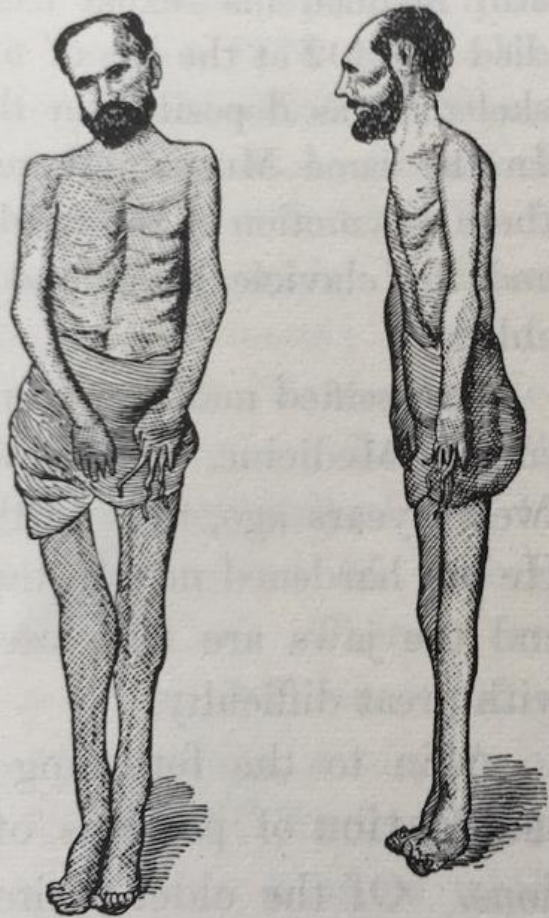
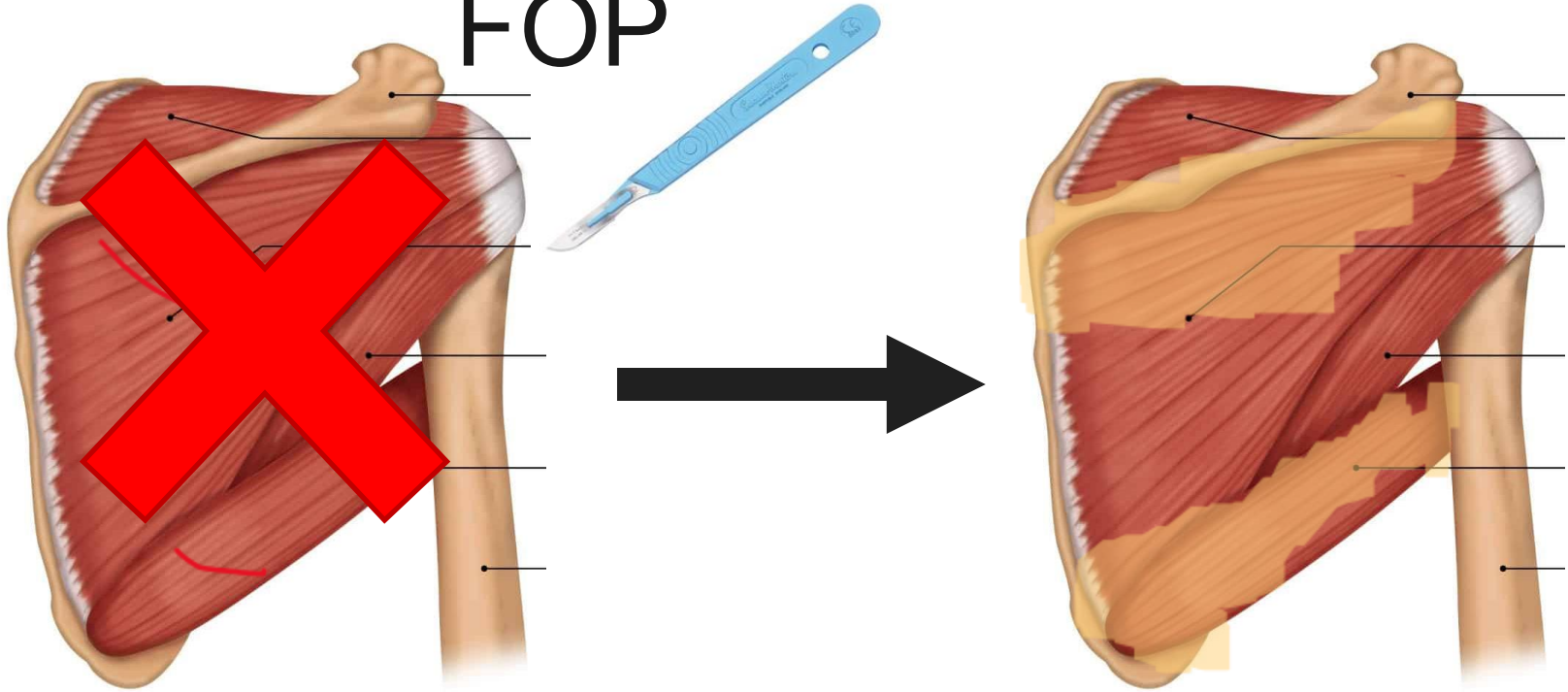

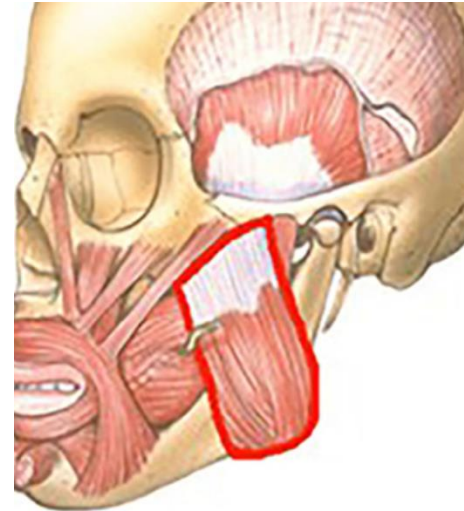


Fig. 268.—Ossified man (front and side views).



# DO NOT BIOPSY FOP

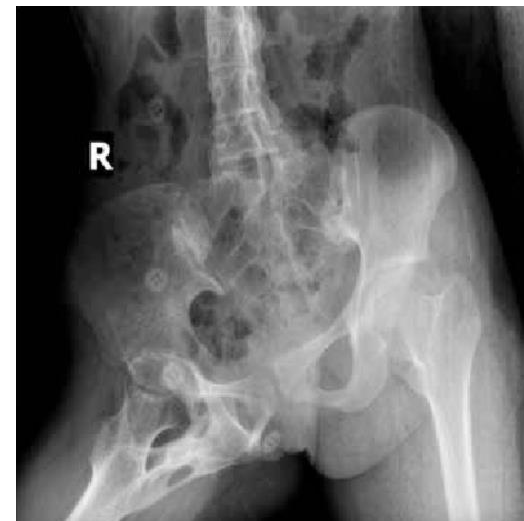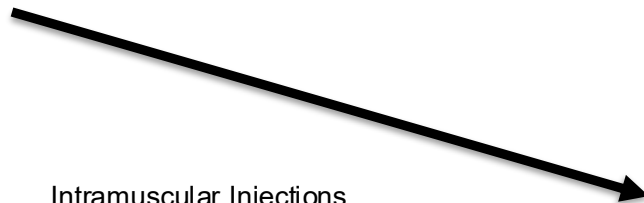




Mandibular Blocks

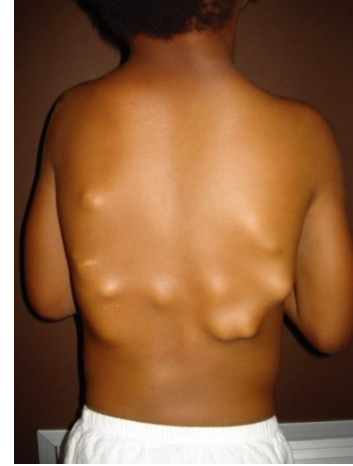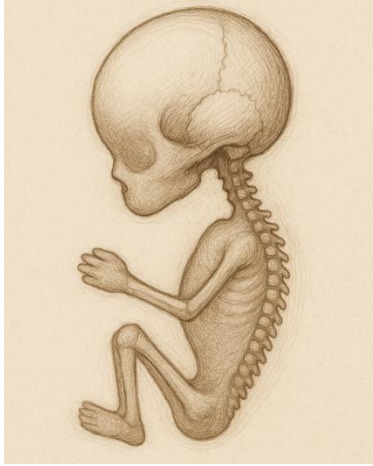


Intramuscular Injections



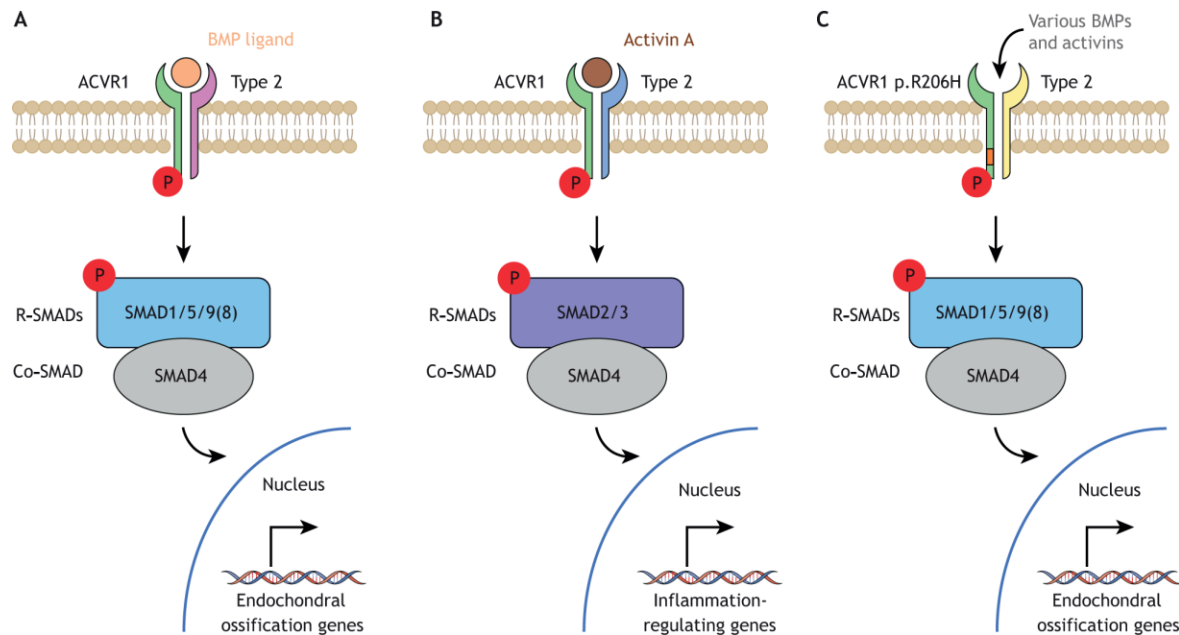


# Embryonal Progression of Ossification

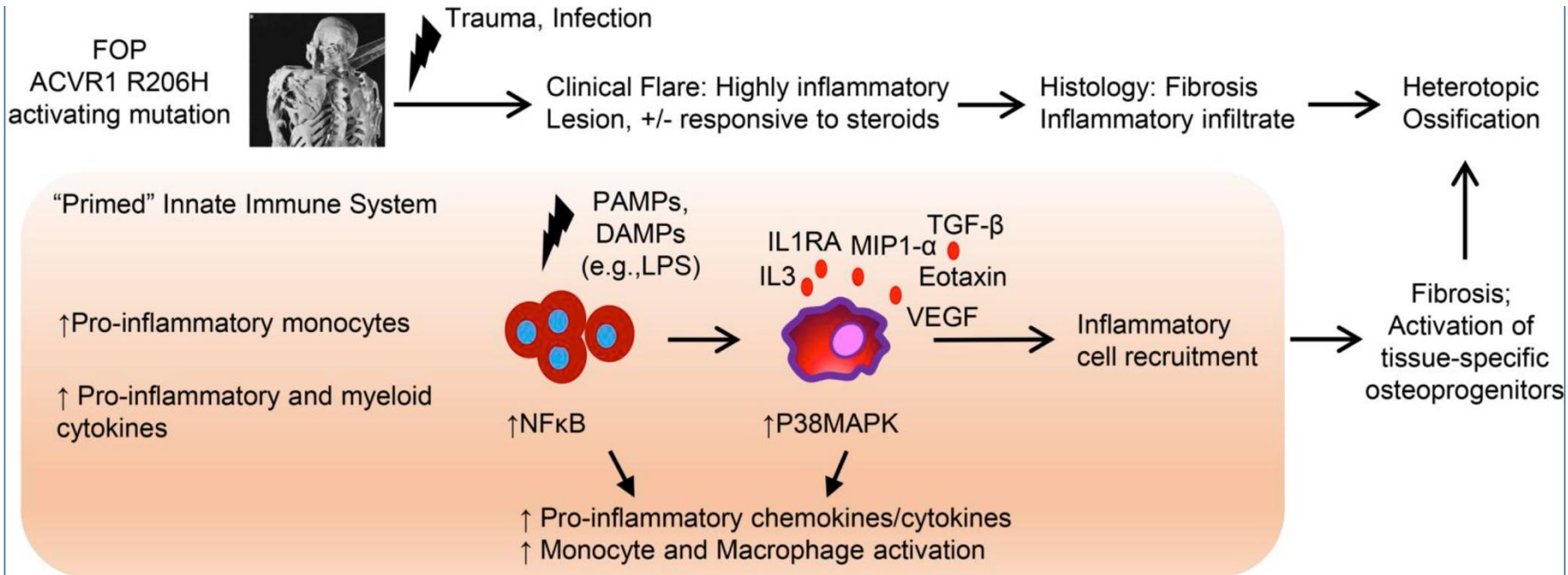


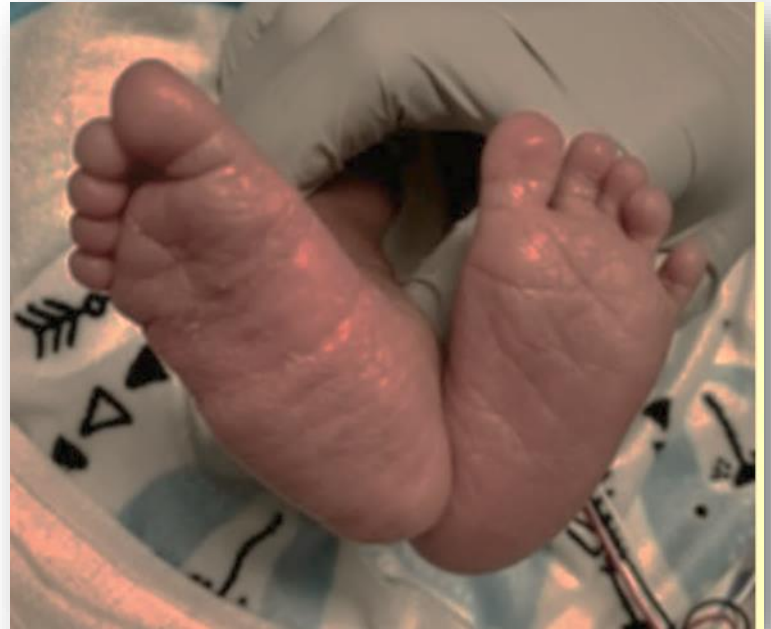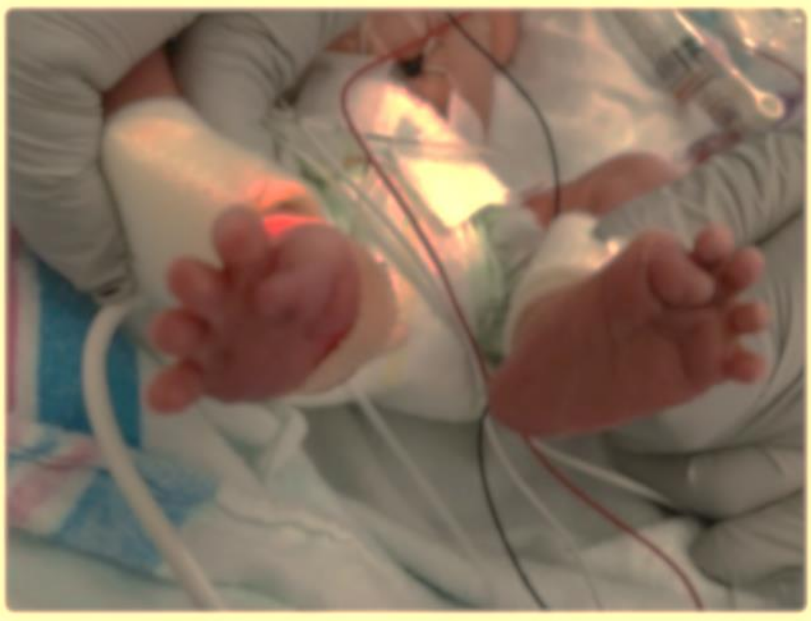- BMPs have an important role in embryonic patterning and early skeletal formation
- BMP4 help regulate polarity of the embryo (i.e. back to front patterning)
- ACVR1/ALK2 regulates BMP activity
- A missense mutation of ACVR 1 causes FOP

Fig. 2.



**Fibrodysplasia ossificans progressiva: current concepts from bench to bedside**





*Cases that illustrate management of*

*FOP*

*Pt A - Fracture and Management*

# The Fall

High fracture risk - falls, immobility, chronic prednisone, palovarotene: ↓ BMD, ↑ fracture risk

Fall in hospital while being assessed for wheelchair

Fractured Orbit

Managed non operatively

Outcome: healed fully, no new ossification

# Falls

Protective gear

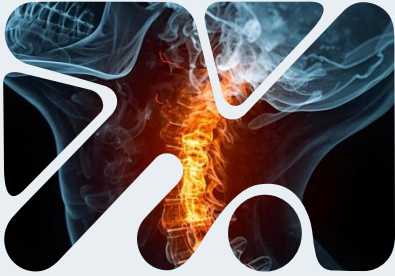

Shoes

Flooring

Walking aids

# Fracture Management Steps

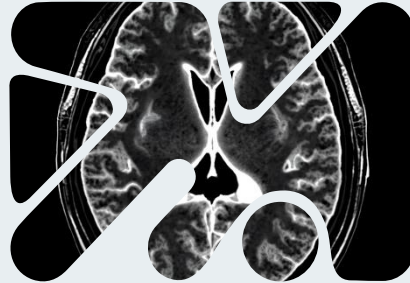

## Stabilise

Standard trauma Care

Gentle handling

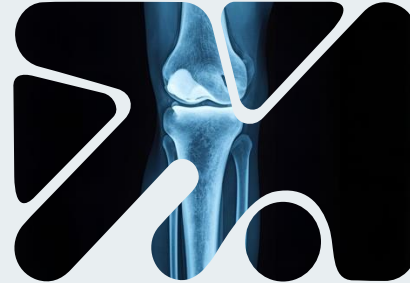
✗ Avoid IM /mandibular  
blocks



## Image

X-rays ± CT/MRI/US

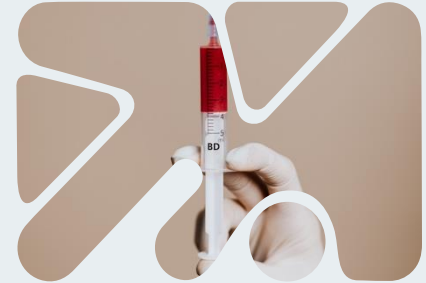Airway & neck precautions



## Conservative Care

Immobilize / cast

Padding & skin checks



## Steroids

Prednisone 2 mg/kg/day  
(max 100 mg)

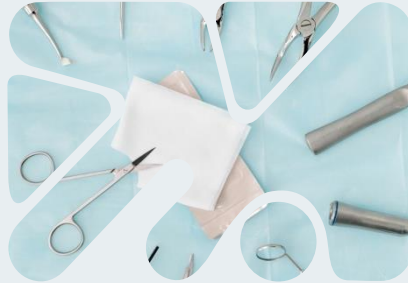Up to 4 days, start <24 h

# Fracture Management Steps



## Analgesia

Standard regimens (avoid IM)  
✗ No passive ROM



## Surgery

🚑 Life-/limb-saving only  
✗ Never remove HO



## Follow-up

6 weeks ~ 97% union  
~7–10% flare / HO / loss of motion



## Long-Term

Fall-prevention  
Nutrition (Ca/Vit D)  
Consider anti-resorptives post-healed fragility fracture

# Nutritional Challenges

Feeding difficulties in advanced disease (jaw ankylosis, thoracic restriction)

Chronic inflammation → altered metabolism & appetite

Long-term **glucocorticoids** → ↓ bone density, ↑ risk of deficiencies

# Iron Considerations

No direct evidence that FOP causes iron deficiency

## **Possible contributors:**

Poor intake due to feeding limitations

Chronic inflammation → functional iron deficiency / anaemia of chronic disease

*CASE 2: Pt B Senior - Surgery in FOP*

# PT B - DENTECTOMY

Severe jaw ossification

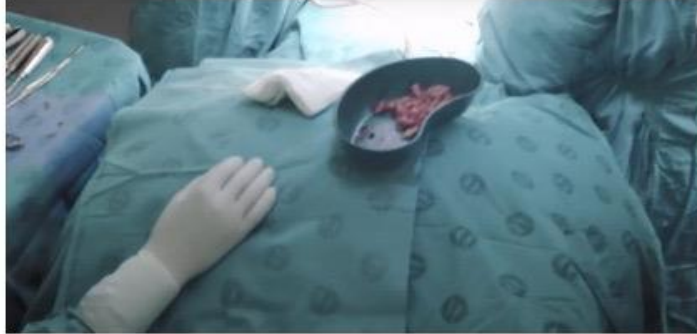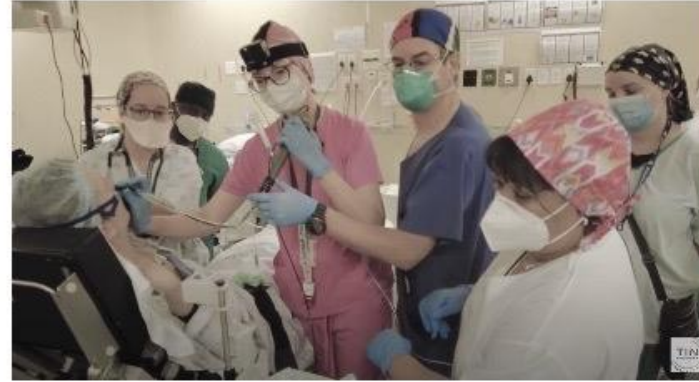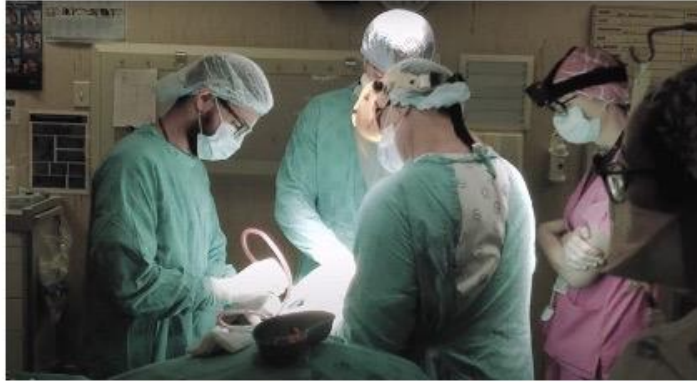Required dental surgery

Pre-op: dexamethasone protocol, fiberoptic intubation

Outcome: successful, minimal new HO

Discuss perioperative risk & planning

# Anaesthesia



If must: get expert help!

Airway maintenance  
Neck issues, jaw issues  
Neck flare up

Avoid if can

# PT B - ANAESTHESIA IN FOP

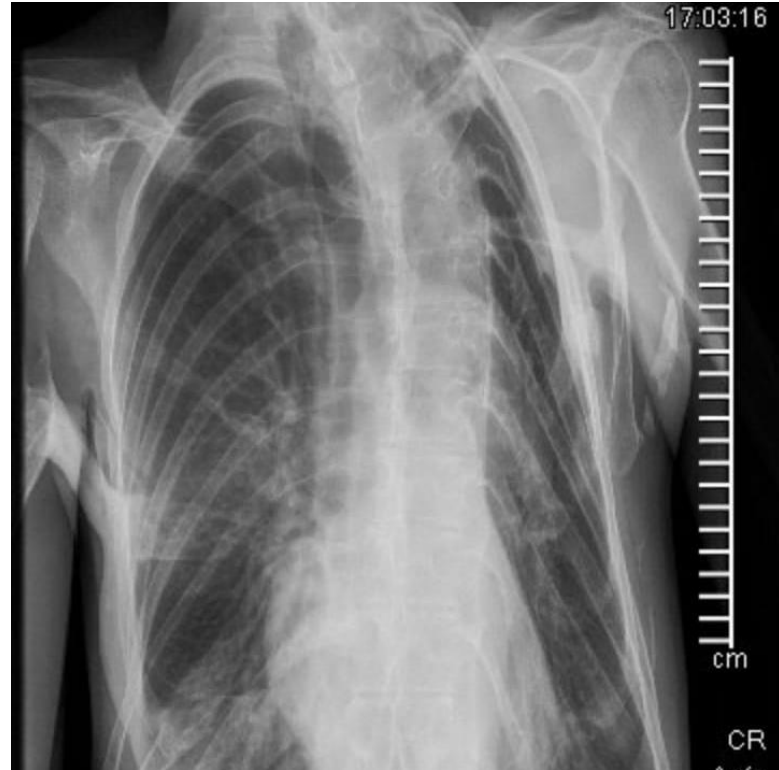
Key concerns: C-spine immobility, ankylosis

Use fiberoptic nasal intubation

Avoid IM injections

Steroid pre-treatment may reduce surgical trauma response

Reference: FOP Anesthesia Guidelines 2022



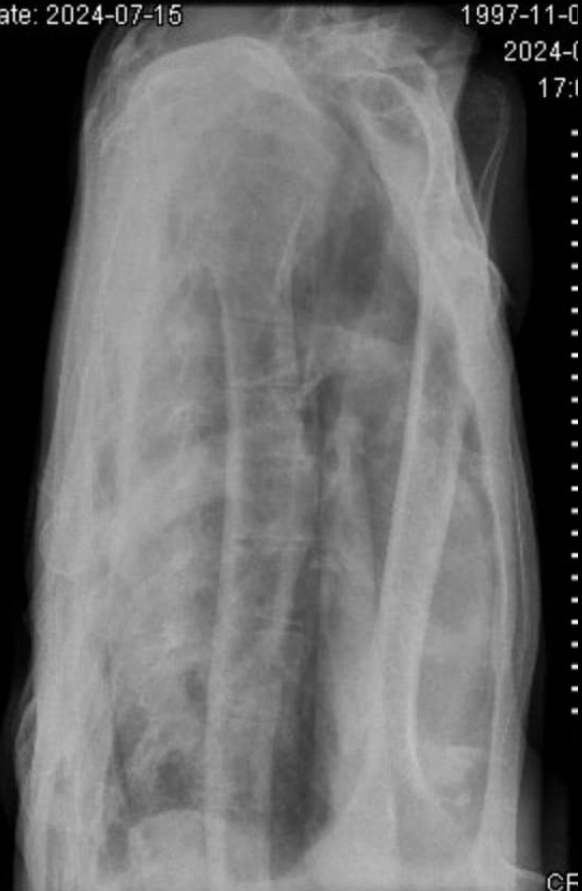Series Date: 2024-07-15

1997-11-0

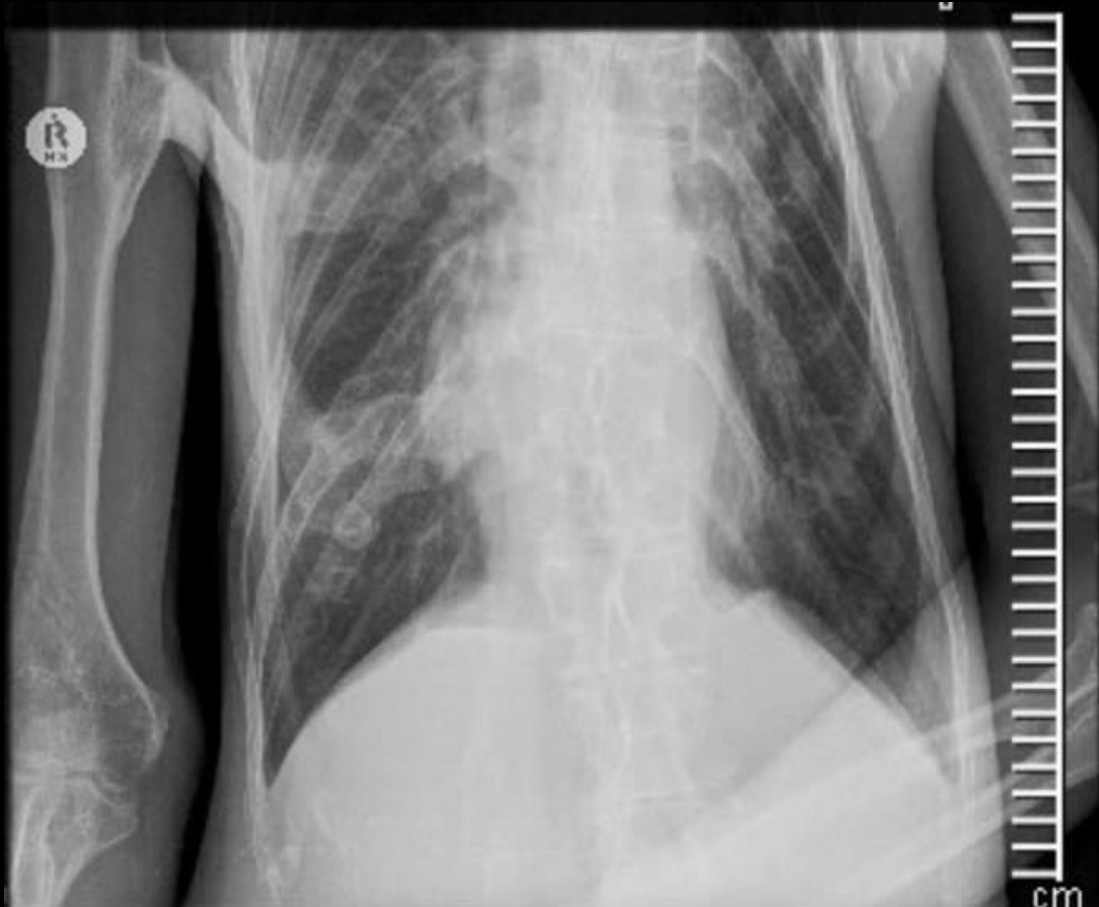2024-0

17:1

□

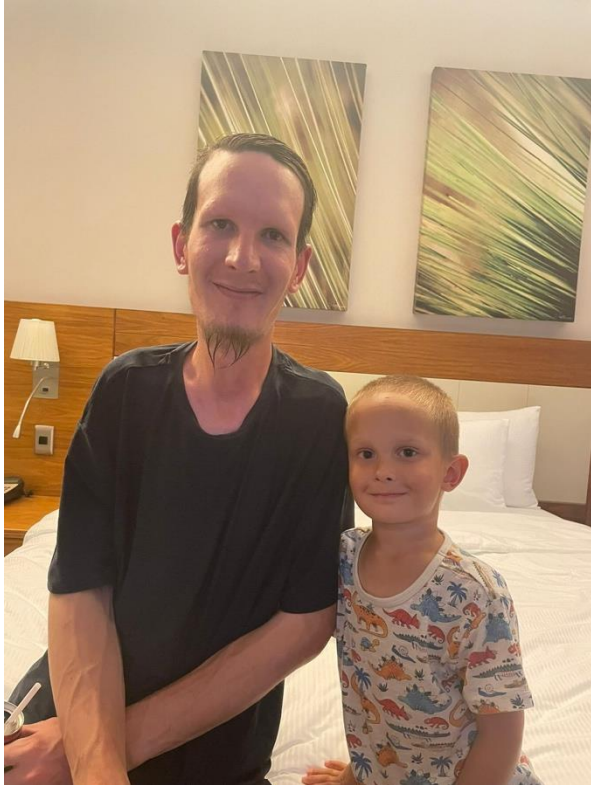

CF



cm

# CASE 3: Pt B Junior - Early Diagnosis, Family Lessons




*He was just there with his father.*

*But subtle signs caught our eye...*


*Neck stiffness. Toe malformations.*

*Together → they told the story of FOP.*


# CASE 3: Pt B Junior - Early Diagnosis, Family Lessons



Early detection may begin with **subtle neck stiffness** observed during routine examinations by healthcare provider.



Confirming diagnosis typically involves screening for **toe malformations** alongside **ACVR1 gene testing** to verify the presence of FOP.



Currently, no treatment exists, so preventive measures are crucial. **Avoiding trauma, dental work, and using subcutaneous vaccines** are essential strategies.

---

# Power of Early Diagnosis

PT B's experience enabled early detection in his son

Emphasize family screening in confirmed cases



*This is not just about managing disease when it appears, it's about shaping the course of the condition through vigilance, prevention, and education*

# Treatment Guidelines

Why?

Improve care  
Offer guidance  
Interpret evidence  
Share experience

For Whom?


All healthcare workers  
FOP community

How?

21 ICC  
7 consultants  
15 countries

Delphi  
Evidence base (>2900 papers)

What are they (what are they not)



*“The medical management of fibrodysplasia ossificans progressiva: current treatment considerations. Proc Intl Clin Council FOP 3:1-159, 2024.”*



**RECOMMENDATIONS**



**MEDICINE**



**EMERGENCIES**

# General Recommendations

Limb Swelling  
Surgery  
Anesthesia  
Lung health  
Chronic Pain  
Nutrition  
Immunizations  
COVID-19

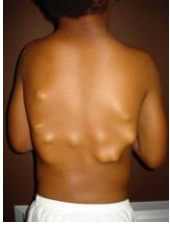Physical Activity  
GIT issues  
Pregnancy  
Hearing  
Skin  
Influenza

Dental care  
Flare ups  
Falls  
Mental Health  
School  
IV's

Kidney Stones  
Fractures  
Pressure Ulcers  
Neurologic  
Injuries  
Physio/OT

Orthodontics

# Flare ups

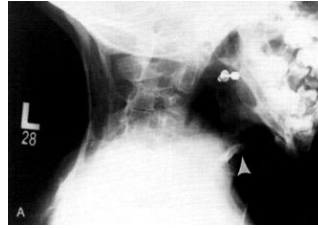


Back or Chest

NSAIDS (e.g. Ibuprofen)

Avoid: Narcotic Analgesia

Maybe Steroids

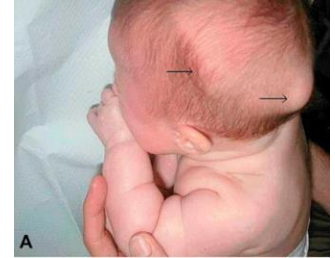

Limbs/throat/face

Prednisone

Pill in pocket

Up to 4 days



Scalp

Observe

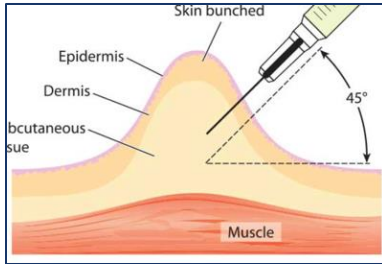
Resolved

Infants

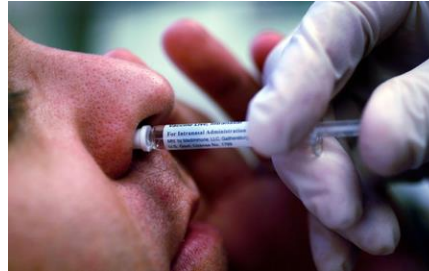Remember stomach protection for NSAIDS and Steroids

**Images:**  
*Scott et al*  
*Kaplan et al*  
*Piram et al*

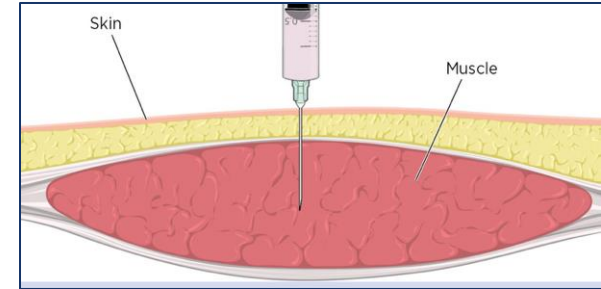
# Immunizations



Avoid Live



Avoid intranasal Flu-vaccine

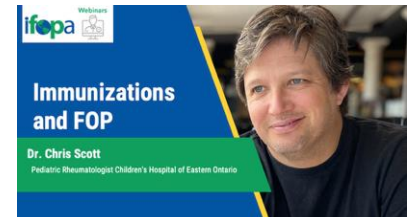

Avoid IMI

Not During Flare ups (8 weeks)

Immunize the family!

ICC Website and  
IFOPA lecture



# Hearing

Hearing Loss is  
common



Screen yearly

Manage

# Approved Medications

## Palovarotene:

Registered in Australia/Canada and USA

Regulatory issues

Prophylaxis and Flare up dosing

Side Effects

Cost

Growth Issues

EXPERT OPINION ON PHARMACOTHERAPY  
2025, VOL. 26, NO. 3, 291–299  
<https://doi.org/10.1080/14656566.2025.2452938>



REVIEW

OPEN ACCESS Check for updates

### Palovarotene in fibrodysplasia ossificans progressiva: review and perspective

Vincent A. Verheij<sup>a</sup>, Robert J. Diecidue<sup>b</sup>, Esmée Botman<sup>a</sup>, Joseph D. Harrington<sup>b</sup>, Nobuhiko Haga<sup>c</sup>, Alberto Hidalgo-Bravo<sup>d</sup>, Patricia L. R. Delai<sup>e</sup>, Vrisha Madhuri<sup>f</sup>, Mona Al Mukaddam<sup>g</sup>, Keqin Zhang<sup>b</sup>, Tae-Joon Cho<sup>h</sup>, Rolf Morhart<sup>i</sup>, Richard Keen<sup>k</sup>, Carmen L. De Cunto<sup>l</sup>, Clive S. Friedman<sup>m</sup>, Zvi Grunwald<sup>b</sup>, Michael Zasloff<sup>n</sup>, J. Coen Netelenbos<sup>a</sup>, Edward Hsiao<sup>o</sup>, Frederick S. Kaplan<sup>g</sup>, Robert J. Pignolo<sup>p</sup>, Christiaan Scott<sup>q,r</sup> and Elisabeth Marelise W. Eekhoff<sup>a</sup>



August 16, 2023

Statement regarding palovarotene from the International Clinical Council (ICC) on FOP

**Premature Epiphyseal Closure:**

Premature epiphyseal closure occurred with SOHONOS. Assess baseline skeletal maturity before SOHONOS therapy and monitor linear growth in growing pediatric patients. Growing pediatric patients are recommended to undergo baseline assessment of growth and skeletal maturity before starting treatment and continued clinical and radiographic monitoring every 6 to 12 months until patients reach skeletal maturity or final adult height.

**Mucocutaneous Adverse Reactions:**

Dry skin, lip dry, pruritus, rash, alopecia, erythema, skin exfoliation, and dry eye occurred with SOHONOS. Prevent or treat with skin emollients, sunscreen, artificial tears. Dosage reduction may be required in some patients.

**Metabolic Bone Disorders:**

Decreased vertebral bone mineral content and bone density may occur. Assess for vertebral fracture periodically using radiologic method.

**Psychiatric Disorders:** Depression, anxiety, mood alterations and suicidal thoughts and behaviors occurred with SOHONOS. Contact healthcare provider if new or worsening symptoms develop in patients treated with SOHONOS.

**Night Blindness:** May occur and make driving at night hazardous

**Pregnancy:** May cause fetal harm.

54% Reduction in HO

10.9cm<sup>3</sup> vs 21.cm<sup>3</sup>

Change in function  
could not be shown

Flare up rate not better

54% of participants withdrew:  
30% by choice, 10% Adverse Events

# Class 1 Medications (Generally Accepted)

Prednisone

NSAID

Ibuprofen  
Indomethacin  
Celecoxib

# Class 2 Medication

(Off Label i.e. approved for other conditions but used in FOP on a case-by-case basis)

Montelukast

Pamidronate

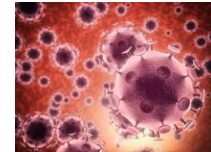
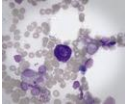
Tofacitinib

Imatinib

Cromolyn

Zoledronate

Canakinumab



30 May 2024

Updated statement regarding off label medications for the management of FOP, from the International Clinical Council (ICC) on FOP

This statement updates the recommendations from the ICC to include several new publications, and brings attention to an important potentially severe medication interaction with palovarotene.

Class 3 Medication  
(In clinical trials)

ACVR1/ALK2  
Signal Transduction Inhibitor, STI  
(Saracatinib) [Astra Zeneca; STOPFOP]

ACVR1/ALK2  
Signal Transduction Inhibitor, STI  
(Fidrisertib; IPN60130) [Ipsen; FALKON]


ACVR1/ALK2  
Signal Transduction Inhibitor, STI  
(Zilurgisertib; INCB000928) [Incyte; PROGRESS]

mTOR  
Inhibitors  
(e.g., Sirolimus) [Kyoto University]


Monoclonal Antibody Against  
Activin A  
(Garetosmab) [Regeneron; Lumina/Optima]

Monoclonal Antibody Against MMP-9  
(Andecaliximab) [āshibio; ANDECAL]

# Key Clinical Reminders



**Check the Toes**



**Avoid Biopsies  
and invasive  
trauma**



**Keep up with  
trials for  
promising  
treatments**

---

Know referral pathways: ICC, IFOPA, Tin Soldiers



MSK CONDITIONS

CLINICIAN CHAMPIONS ALLIANCE

FOR HEALTHCARE PROFESSIONALS

ABOUT US

PROJECTS

RESOURCES



100% of patients with a rare musculoskeletal condition are diagnosable.

## EDUCATE. DIAGNOSE. REFER

Our driving force is to promote early diagnosis, by educating clinicians, to ensure we put all children, as early as possible, on a pathway of care that serves them.

## LET US HELP

If you or a loved one have or think you have FOP or another paediatric musculoskeletal condition, please **contact us** today.

[LEARN MORE](#)